

Case Report

Johanson-Blizzard syndrome: a report of gender-discordant twins with a novel *UBR1* mutation

C.R. Quaio¹, Y.K. Koda², D.R. Bertola¹, M. Sukalo³, M. Zenker³ and C.A. Kim¹

¹Unidade de Genética, Instituto da Criança, Faculdade de Medicina, Universidade de São Paulo, São Paulo, SP, Brasil

²Unidade de Gastroenterologia, Instituto da Criança, Faculdade de Medicina, Universidade de São Paulo, São Paulo, SP, Brasil

³Institute of Human Genetics, University Hospital Magdeburg, Magdeburg, Germany

Corresponding author: C.A. Kim
E-mail: chong.kim@icr.usp.br

Genet. Mol. Res. 13 (2): 4159-4164 (2014)

Received January 8, 2013

Accepted December 4, 2013

Published June 9, 2014

DOI <http://dx.doi.org/10.4238/2014.June.9.2>

ABSTRACT. Johanson-Blizzard syndrome (JBS) is a rare autosomal recessive disorder resulting from loss-of-function mutations in the *UBR1* gene. JBS can be easily recognized by its unique clinical presentation (including exocrine pancreatic insufficiency, hypoplasia/aplasia of the alae nasi, congenital scalp defects, sensorineural hearing loss, growth retardation, psychomotor retardation, and anal and genitourinary anomalies). The objective of this study is to report on the first familial case of gender-discordant twins presenting JBS and a novel mutation in the *UBR1* gene. We also review literature describing molecularly confirmed cases of JBS. The female twin developed refractory severe diarrhea after the second month of life and died at the

age of 3 months. The male twin also developed diarrhea and failure to thrive after the 3 month of life but improved when nutrition support and pancreatic enzyme replacement was started, and he has survived into adolescence. Both patients presented typical clinical features of JBS. A homozygous nonsense mutation (c.3682C>T; p.Q1228X) in *UBR1* was confirmed. Severe presentation of JBS usually involves deleterious (nonsense, frameshift, or splice-site) mutations in the *UBR1* gene that are thought to completely abolish the expression of a functional protein product, as in this familial case; however, milder presentation of JBS has occasionally been observed with missense mutations in at least 1 of the 2 copies of *UBR1*, in which there may be residual activity of the product of this gene. Early diagnosis and adequate treatment are crucial for a favorable outcome.

Key words: Pancreatic disease; Exocrine pancreatic insufficiency; Clinical analysis; Gene expression

INTRODUCTION

Johanson-Blizzard syndrome (JBS) is a rare autosomal recessive disorder resulting from loss-of-function mutations in the *UBR1* gene, which is located on chromosome 15q15-21 (Varshavsky, 1996; Kwon et al., 1998; Kwak et al., 2004; Zenker et al., 2005; Almashraki et al., 2011; Fallahi et al., 2011; Rezaei et al., 2011). Although JBS can be easily recognized by its unique clinical presentation (including exocrine pancreatic insufficiency, hypoplasia/aplasia of the alae nasi, congenital scalp defects, sensorineural hearing loss, growth retardation, **psychomotor retardation**, and anal and genitourinary anomalies), the detailed pathophysiological connection between the altered product of the *UBR1* gene and the clinical anomalies observed in JBS remains to be determined. The severity of clinical features can vary greatly from case to case, but the literature still lacks systematic genotype-phenotype correlation studies (Varshavsky, 1996; Kwon et al., 1998; Kwak et al., 2004; Almashraki et al., 2011).

The objective of this study is to report on the first familial case of gender-discordant twins presenting JBS and a novel mutation in the *UBR1* gene. We also reviewed literature describing molecularly confirmed cases of JBS.

CASE REPORT

Gender-discordant twin siblings were the product of a full-term pregnancy of healthy, young, non-consanguineous parents. The female twin (BW: 2250 g; small for gestational age) was born in good clinical condition, but with distinct facies that included hypoplastic nasal alae. She developed refractory severe diarrhea after the second month of life and died at the age of 3 months. No autopsy was performed.

The male twin (BW: 2250 g; small for gestational age) was also born in good clinical condition, presented the same facial characteristics and developed severe diarrhea after the third month of life. The child required several hospital admissions to treat refractory diar-

rhea, dehydration, and malnutrition and experienced cardiorespiratory arrest at 4 months of age. Physical examination at the age of 5 months revealed severe failure to thrive (W: 2430 g; L: 50 cm; OFC: 35.5 cm), hypoplastic nasal alae, posterior aplasia cutis, axial hypotonia, and unilateral cryptorchidism. The patient's general condition and weight gain considerably improved when nutritional support and pancreatic enzyme replacement was initiated at the age of 5 months, resulting in a favorable outcome. The treatment consisted of a high-calorie diet with 30 to 40% calories from fat, 2500 lipase U/kg meal, and fat-soluble vitamins (A, D, E, and K), as well as mineral supplementation.

The male twin had a normal echocardiogram, abdominal ultrasonography and karyotype (46,XY). Hearing evaluation revealed deep bilateral neurosensory deafness. His developmental milestones were delayed (sat at 3 years old, walked at 4 years and 6 months); he had conical teeth and agenesis or hypoplasia of 11 teeth.

The patient is now 13 years old. All of his anthropometric measurements have remained below the fifth percentile for the normal population (W: 24.2 kg; H: 121.5 cm; OFC: 49 cm) despite nutritional support and pancreatic enzyme replacement therapy (Figure 1). He is able to communicate with gestures and has learning difficulties.

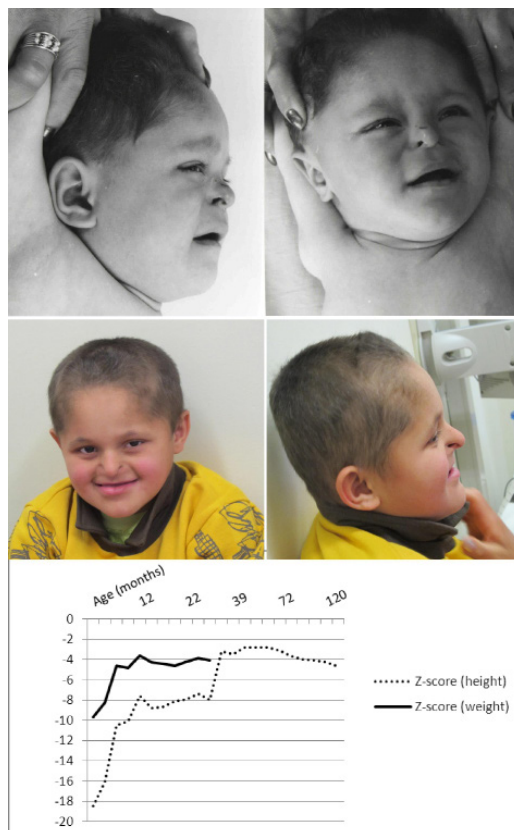


Figure 1. Male twin with Johanson-Blizzard syndrome. The first row shows the patient at 8 months old, while the second row shows the patient at 14 years; the third row shows the Z-score of height and weight over the years (LMS Parameters for Boys; National Health and Nutrition Survey (NHANES), CDC/National Center for Health Statistics).

Genetic studies

Molecular genetic analysis of the *UBR1* gene to confirm the suspicion of JBS was performed by direct sequencing of all 47 known coding exons and the flanking intron regions using an ABI3730 automated sequencer (Applied Biosystems, Carlsbad, CA, USA). A novel nonsense mutation (c.3682C>T; p.Q1228X) was identified in the homozygous state in the affected male twin. Parental samples were not available for testing. Thus, the possibility cannot be excluded that the mutation was hemizygous in the patient, with a larger deletion on the second allele. In any case, genetic testing confirmed the diagnosis.

DISCUSSION

Here, we described gender-discordant twins with JBS and reported a novel mutation in the *UBR1* gene. The different outcomes presented by these siblings from the same family, and most likely with the same mutation (molecular confirmation was not possible for the female twin), were mainly determined by early initiation of nutritional support and pancreatic enzyme replacement, making it possible for the male twin to survive into adolescence. As the twins are necessarily dizygotic, 2 independent events must have occurred to form 2 affected embryos (1/16 chance for dizygotic twins).

The *UBR1* product is an ubiquitin ligase (E3) and part of the N-end rule pathway of the ubiquitylation system, which regulates the degradation and half-lives of many intracellular proteins (Varshavsky, 1996; Kwon et al., 1998; Kwak et al., 2004; Zenker et al., 2005). This protein is broadly expressed, with the highest levels observed in skeletal muscle, kidney, and pancreas (mainly in acinar cells), and the protein has 3 regions: a UBR-type Zinc finger domain, a poly-Pro domain, and a RING-type Zinc finger domain.

Although more than 60 cases have been reported worldwide, less than 20 cases have a molecular confirmation of mutations in the *UBR1* gene, with more than 20 different mutations, as shown in Figure 2. A severe presentation of JBS usually involves deleterious (nonsense, frameshift, or splice-site) mutations in the *UBR1* gene that are thought to completely abolish the expression of a functional protein product (Zenker et al., 2005; Alkhouri et al., 2008; Fallahi et al., 2011; Hwang et al., 2011). However, milder involvement of JBS is associated with missense mutations in at least 1 of the 2 copies of *UBR1*, in which residual activity of the product of this gene would prevent a more severe clinical manifestation (Hwang et al., 2011). Notably, the severity of the clinical features can vary greatly from case to case, making it difficult to establish definite genotype-phenotype correlations (Varshavsky, 1996; Kwon et al., 1998; Kwak et al., 2004; Almashraki et al., 2011).

The male twin presented typical clinical features of JBS (listed in order of prevalence in patients with JBS): pancreatic insufficiency (98%), nasal alae hypoplasia (98%), dental hypoplasia/agenesis (96%), short stature (84%), scalp defects (72%), deafness (69%), and **mental retardation (69%)** (Al-Dosari et al., 2008; Alkhouri et al., 2008; Elting et al., 2008; Almashraki et al., 2011; Fallahi et al., 2011; Hwang et al., 2011).

The early onset of the clinical manifestation of JBS is also remarkable, with pancreatic exocrine deficiency beginning usually in the first months of life. Thus, prompt treatment is crucial for a better outcome. The differential diagnosis of congenital exocrine pancreatic insufficiency must include cystic fibrosis (meconium ileus and pulmonary involvement),

Shwachman-Diamond syndrome (intermittent neutropenia/pancytopenia and metaphyseal chondrodysplasia), Pearson Marrow-Pancreas syndrome (macrocytic anemia and renal tubular dysfunction), and congenital pancreatic agenesis (neonatal diabetes mellitus), among others. All of these conditions may be differentiated from JBS by the latter's unique facial characteristics.

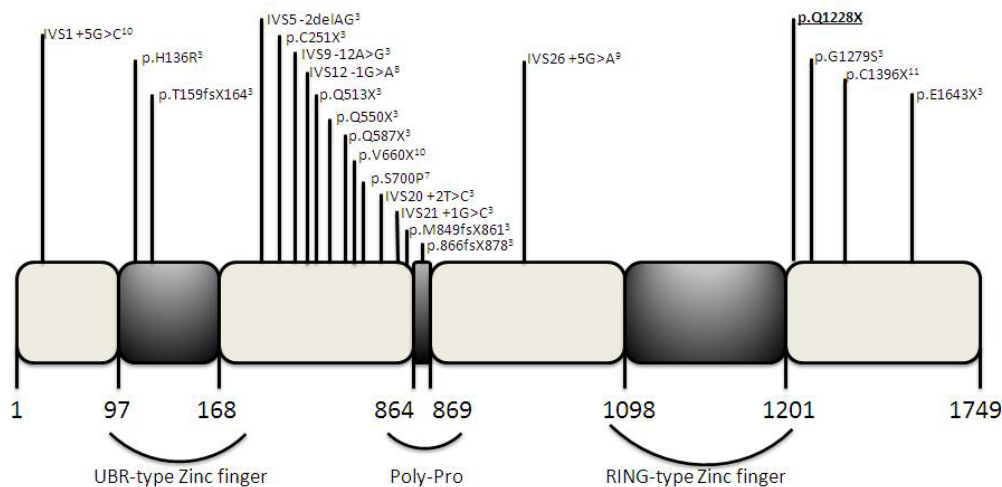


Figure 2. Schematic of the product of the *UBR1* gene, its regions (UBR-type Zinc finger, Poly-Pro and RING-type Zinc finger) and the distribution of mutations from patients with JBS reported in the literature. The novel mutation reported in this article (p.Q1228X) is presented in bold and underlined.

In conclusion, we described a familial case of gender-discordant twins presenting JBS with a novel mutation in the *UBR1* gene and reviewed the literature describing molecularly confirmed cases of JBS. Severe expression of JBS usually involves deleterious (nonsense, frameshift, or splice-site) mutations in the *UBR1* gene that are thought to completely abolish the expression of a functional protein product. Early diagnosis and adequate treatment are crucial for a favorable outcome.

REFERENCES

- Al-Dosari MS, Al-Muhsen S, Al-Jazaeri A, Mayerle J, et al. (2008). Johanson-Blizzard syndrome: report of a novel mutation and severe liver involvement. *Am. J. Med. Genet. A* 146A: 1875-1879.
- Alkhouri N, Kaplan B, Kay M, Shealy A, et al. (2008). Johanson-Blizzard syndrome with mild phenotypic features confirmed by *UBR1* gene testing. *World J. Gastroenterol.* 14: 6863-6866.
- Almashraki N, Abdulnabee MZ, Sukalo M, Alrajoudi A, et al. (2011). Johanson-Blizzard syndrome. *World J. Gastroenterol.* 17: 4247-4250.
- Elting M, Kariminejad A, de Sonnaville ML, Ottenkamp J, et al. (2008). Johanson-Blizzard syndrome caused by identical *UBR1* mutations in two unrelated girls, one with a cardiomyopathy. *Am. J. Med. Genet. A* 146A: 3058-3061.
- Fallahi GH, Sabbaghian M, Khalili M, Parvaneh N, et al. (2011). Novel *UBR1* gene mutation in a patient with typical phenotype of Johanson-Blizzard syndrome. *Eur. J. Pediatr.* 170: 233-235.
- Hwang CS, Sukalo M, Batygin O, Addor MC, et al. (2011). Ubiquitin ligases of the N-end rule pathway: assessment of mutations in *UBR1* that cause the Johanson-Blizzard syndrome. *PLoS One* 6: e24925.

- Kwak KS, Zhou X, Solomon V, Baracos VE, et al. (2004). Regulation of protein catabolism by muscle-specific and cytokine-inducible ubiquitin ligase E3alpha-II during cancer cachexia. *Cancer Res.* 64: 8193-8198.
- Kwon YT, Reiss Y, Fried VA, Hershko A, et al. (1998). The mouse and human genes encoding the recognition component of the N-end rule pathway. *Proc. Natl. Acad. Sci. U. S. A.* 95: 7898-7903.
- Rezaei N, Sabbaghian M, Liu Z and Zenker M (2011). Eponym: Johanson-Blizzard syndrome. *Eur. J. Pediatr.* 170: 179-183.
- Varshavsky A (1996). The N-end rule: functions, mysteries, uses. *Proc. Natl. Acad. Sci. U. S. A.* 93: 12142-12149.
- Zenker M, Mayerle J, Lerch MM, Tagariello A, et al. (2005). Deficiency of UBR1, a ubiquitin ligase of the N-end rule pathway, causes pancreatic dysfunction, malformations and mental retardation (Johanson-Blizzard syndrome). *Nat. Genet.* 37: 1345-1350.